

Dermatologic surgery

# Treatment of refractory melasma with combination of topical 5% magnesium ascorbyl phosphate and fluorescent pulsed light in Asian patients

Zafar I. Shaikh<sup>1,2</sup>, MBBS, FCPS and Ashar A. Mashood<sup>3</sup>, MBBS, FCPS

<sup>1</sup>Department of Dermatology, Army Medical College, Rawalpindi, Pakistan, <sup>2</sup>Department of Dermatology, Military Hospital, Rawalpindi, Pakistan, and <sup>3</sup>Combined Military Hospital, Kohat, Pakistan

## Correspondence

Zafar I. Shaikh, MBBS, FCPS  
Department of Dermatology  
Military Hospital  
Rawalpindi 46000  
Pakistan  
E-mail: zaf\_114@yahoo.com

Conflicts of interest: None.

doi: 10.1111/ijd.12195

## Abstract

**Background** Melasma is an acquired disorder of hypermelanosis of great psychosocial concern. The treatments with various conventional therapies are often unsatisfactory. Lasers and light sources have been used to treat pigmented lesions, but in Asian skin with higher melanin content, such treatments may be challenging.

**Objectives** To determine the effectiveness of treating melasma with a combination of topical 5% magnesium ascorbyl phosphate (MAP) and fluorescent pulsed light (FPL).

**Materials and methods** Patients of skin types III–V with refractory melasma were treated for 12 weeks with topical application of 5% MAP and three sessions of FPL (570–950 nm) at 3, 6, and 9 weeks (fluence 12–14 J/cm<sup>2</sup>, pulse width 15 ms, and spot size 3 cm<sup>2</sup>). They were followed up for another 12 weeks to assess the persistence of treatment benefit.

Digital photographs of the patients were taken at each visit. Treatment efficacy was determined by calculating mean melasma area and severity index (MASI) at the beginning and then at weeks 6, 12, and 24. The subjective assessment was done by comparing pre-treatment and post-treatment photographs by an independent observer and self-assessment by patients using four-point scoring scale (1, poor, 2, fair, 3, good, and 4, excellent).

**Results** Sixty-five patients completed the study. The baseline mean MASI score of 14.80 decreased to 4.53 at the 12th week (end of treatment) and 6.35 at the 24th week (end of follow-up). The overall regression of mean MASI at these end-points was 69.3% and 57% ( $P < 0.01$ ). The pre- and post-treatment photographic evaluation by independent observer and patients' self-assessment at the 12th week showed good to excellent response (scores 3 and 4) in 52.3% and 44.6% cases, respectively. No significant adverse effects of treatment were noted.

**Conclusion** Combination of 5% MAP with FPL is effective, well tolerated, and safe in treating refractory melasma in Asian patients but for persistent improvement, maintenance treatments would be required.

## Introduction

Melasma is an acquired disorder of hypermelanosis of great psychosocial concern. It is characterized by irregular light brown to dark muddy brown macules and patches involving sun-exposed areas of the face (i.e., cheek, forehead, nose, upper lip, and chin). The pathogenesis of melasma remains largely unknown. It affects millions of people worldwide and is found most commonly in women with Fitzpatrick skin phototypes III–V.<sup>1</sup> The common contributing factors include genetic predisposition, pregnancy, oral contraceptives, endocrine dysfunction, hormonal treatments, drugs containing phototoxic agents,

and stress. Exposure to ultraviolet light is a major triggering or aggravating factor for melasma.<sup>2</sup>

Melasma is classified into three main types: epidermal, dermal, and mixed. The epidermal type is the most common in which the pigmentation appears more intense under Wood's lamp examination. Melanin is distributed throughout the epidermis; topical treatment may work best in this type of melasma. In the dermal type, the pigmentation is not intensified with Wood's light. The pigmentation is due to plenty of melanophages in the dermis. In the mixed type, Wood's light intensifies pigmentation in some areas while other areas remain unchanged. The pigmentation is due to increased epidermal melanin as well

as dermal melanophages.<sup>3</sup> Several therapeutic modalities are being used to treat melasma, which include numerous topical agents, chemical peels, dermabrasion, and a variety of lasers and light-based devices. However, most treatment options had been disappointing with relatively frequent failures, and the term refractory melasma was designated for these cases.<sup>4</sup> The benefit of treating melasma with lasers and intense pulsed light (IPL) is still controversial. In terms of efficacy and recurrence rate, comparable results of laser versus topical therapy were reported, and topical treatment with hydroquinone (HQ) based modified Kligman's formula, also called triple topical therapy (TTT), was considered as the gold standard.<sup>5,6</sup> Nevertheless, to further improve upon the treatment outcomes particularly in refractory cases, combinations of treatment modalities have been tried. These combinations included addition of IPL therapy to HQ-based topical preparations and sun protection;<sup>7</sup> using different lasers and light sources together such as combined use of IPL and Q-switched (QS) ruby laser,<sup>8</sup> and combined use of ultrapulse CO<sub>2</sub> laser and QS alexandrite laser.<sup>9</sup>

Because of the higher melanin content in Asian skin, treatment of pigmented lesions with lasers and light-based devices may be challenging due to increased risk of postinflammatory hyperpigmentation. In an attempt to minimize this risk, we evaluated the combination of 5% magnesium ascorbyl phosphate (MAP) and fluorescent pulsed light (FPL) for treating our patients with refractory melasma. MAP is a stable ester of ascorbic acid that has antioxidant properties and inhibits melanogenesis *in vitro* and *in vivo*. It prevents free-radical production and has a protective effect against ultraviolet B radiation.<sup>10</sup> The FPL is a non-coherent light that differs from conventional IPL by its lower peak power and has been successfully used to treat pigmentation due to stasis dermatitis.<sup>11</sup> The FPL device uses fluorescent polymers to convert the shorter and most harmful wavelengths to more beneficial visible light. In other words, the cut-off or rejected harmful shorter wavelengths of light are not only prevented from hitting the skin but also are passed through a filter that converts them to useful longer therapeutic wavelengths. An additional advantage of FPL device is that one can reduce the lamp voltage (thereby increasing the life of the lamp) and still create a high output to achieve the desired spectral emission.<sup>12</sup>

## Patients and methods

This study was performed on patients with refractory epidermal and mixed melasma having Fitzpatrick skin types from III to V. The patients were recruited from the outpatient clinic of the Dermatology Department, Military Hospital Rawalpindi (Pakistan). The selected patients had shown little or no

improvement in melasma to one or more previously prescribed treatment modalities for a minimum period of six months. These treatments included various topical bleaching agents, chemical peeling, microdermabrasion, laser, or IPL. Before entering the study, they were off-treatment with any of these therapies for at least three months. Patients with a history of photosensitivity, any other skin disease at the area of treatment, pregnancy, and those on contraceptive pills were excluded. All subjects gave written informed consent, and the study protocol was approved by the local medical ethical committee. Patients' characteristics such as age, gender, duration, and type of melasma were recorded.

Selected patients were treated for 12 weeks (treatment phase) with daily topical application of 5% MAP (prepared in a white lanolin base with end pH of 5.5) at night and three sessions of FPL (570–950 nm) with an advanced fluorescent technology device (Harmony<sup>XL</sup> system; Alma lasers, Buffalo Grove, IL, USA) at third, sixth, and ninth weeks (fluence 12–14 J/cm<sup>2</sup>, pulse width 15 ms, pulse repetition rate 2/3 Hz, and spot size 3 cm<sup>2</sup>). The first treatment session in all patients was done at fluence of 12 J/cm<sup>2</sup>, which was increased by 1 J/cm<sup>2</sup> in each of the two subsequent sessions. At each session, two passes were given, and mild erythema was taken as the treatment end-point. After completing the treatment, patients were followed up for the next 12 weeks, during which they were reviewed every four weeks to assess the persistence of treatment benefit (follow-up phase). All patients were advised to use sunscreen (SPF-60) throughout the period of observation. Digital photographs of the patients were taken at each visit.

## Evaluation of treatment efficacy

The objective assessment of treatment efficacy was based on the mean MASI scores, which were calculated at the beginning and then at weeks 6, 12, and 24.

$$\text{MASI} = 0.3(\text{DF} + \text{HF})\text{AF} + 0.3(\text{DMR} + \text{HMR})\text{AMR} + 0.3(\text{DML} + \text{HML})\text{AML} + 0.1(\text{DC} + \text{HC})\text{AC}$$

where D is darkness, H is homogeneity, A is area, F is forehead, MR is right malar, ML is left malar, and C is chin. The values 0.3 and 0.1 are respective percentages of the total facial area.

The subjective assessment was done at the end of the treatment phase (12th week) by an independent observer by comparing pre-treatment and post-treatment photographs of patients, and self-assessment by patients themselves, using a four-point scoring scale: 1, poor (0–25% clearing); 2, fair (26–50% clearing); 3, good (51–75% clearing); and 4, excellent (>75% clearing).

## Safety assessment

The patients were instructed to visit the clinic if they noticed any untoward effects due to topical 5% MAP or FPL treatments

on any working day. At scheduled visits, the possible side effects of these treatments such as erythema, burning, pain, peeling, edema, petechiae, or postinflammatory pigmentary changes were enquired and recorded.

**Statistical analysis**

The statistical analysis of the data was performed using SPSS version 16 software (SPSS Inc., Chicago, IL, USA), which included basic frequencies and statistics (range, mean, and standard deviations). Paired sample *t*-test was used to analyze the pre-treatment and post-treatment means of the MASI scores. Significance was defined as *P* < 0.05.

**Results**

A total of 70 patients were recruited in the study of which five patients were lost to follow-up. The baseline characteristics of 65 patients who completed the study are given in Table 1. There were 13 (20%) patients with epidermal melasma and 52 (80%) patients with mixed melasma, refractory to previous treatments.

**Objective assessment**

The mean MASI scores (Fig. 1) in these patients decreased from a baseline value of 14.80 ± 3.4 to 4.53 ± 1.5 at the 12th week (end of treatment) and 6.35 ± 2.4 at the 24th week (end of follow-up). The overall regression of mean MASI scores at these two endpoints was 69.3% and 57% (*P* < 0.01).

**Subjective assessment**

The assessments done by an independent observer and patients themselves at the end of treatment on the 12th week using a four-point scoring scale are shown in Table 2. Collectively, good to excellent responses to treat-

**Table 1** Characteristics of melasma patients at baseline

Number of patients	65
Gender	
Females	47 (72.3%)
Males	18 (27.7%)
Age	
Range (mean ± SD) years	18–43 (27 ± 8.5)
Duration of melasma	
Range (mean ± SD) months	12–60 (18 ± 9.2)
Fitzpatrick skin types	
III	8 (12.3%)
IV	43 (66.1%)
V	14 (21.5%)
Types of melasma	
Epidermal	13 (20%)
Mixed	52 (80%)
Mean MASI score (SD)	14.80 (± 3.4)

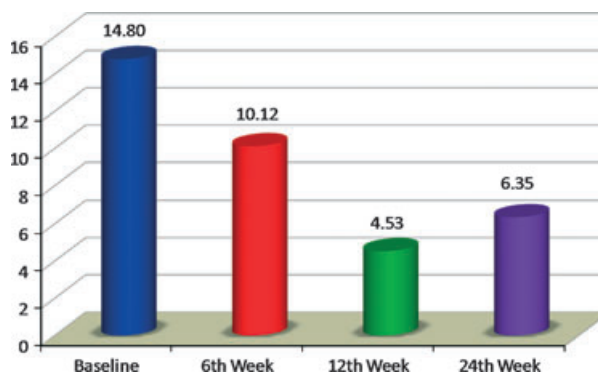
ment (scores 3 and 4) were recorded in 52.3% and 44.6% cases, respectively (Figs. 2 and 3).

**Safety assessment**

No significant adverse effects were noted either due to 5% MAP or FPL in our patients. The erythema observed in five (7.6%) patients and mild skin peeling in four (6.1%) patients after FPL sessions subsided in a few days without any specific treatment. These effects occurred only in patients with Fitzpatrick skin types IV and V after FPL sessions done at a fluence of 14 J/cm<sup>2</sup> (Table 3).

**Discussion**

Melasma is a disorder of great psychosocial concern that lowers individuals self esteem and poses significant negative impact on health-related quality of life.<sup>13,14</sup> Though multiple options exist to treat this condition, no single therapy has proven to be of benefit to all patients.<sup>7</sup> The local side effects and recurrence following cessation of these treatments are frustrating both for physicians and patients. Our patient sample consisted of 13 (20%) patients with epidermal melasma and 52 (80%) with mixed melasma, ranging in duration from 1 to 5 years. All of these patients had undergone treatments with

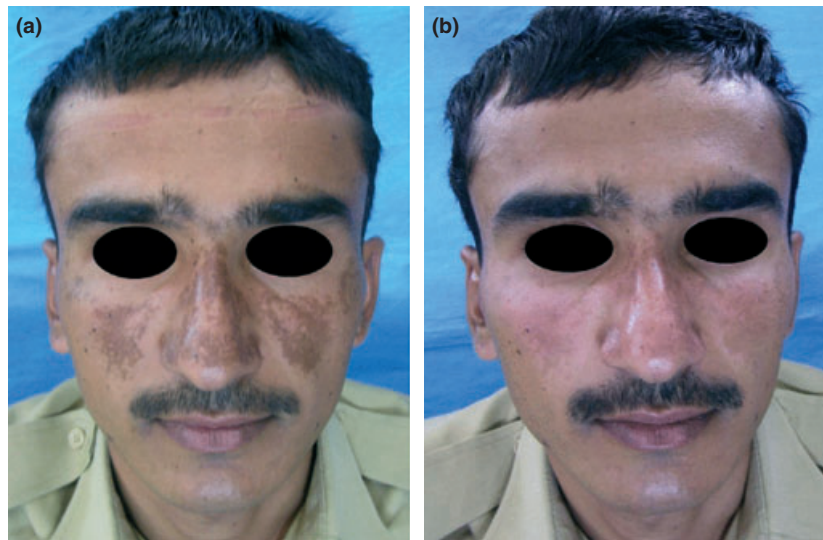

**Figure 1** Reduction in mean melasma area and severity index scores

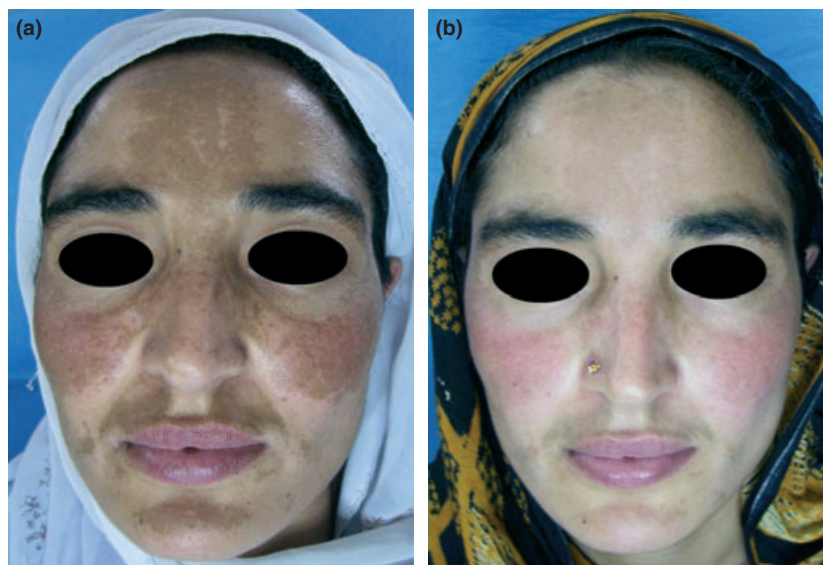**Table 2** Subjective assessment at end of treatment (week 12) (*n* = 65)

Scoring scale	Independent observer	Patients
1 Poor	7 (10.7%)	10 (15.4%)
2 Fair	24 (36.9%)	26 (40%)
3 Good	23 (35.3%)	21 (32.3%)
4 Excellent	11 (16.9%)	8 (12.3%)

FPL, fluorescent pulsed light.



**Figure 2** Pretreatment (a) and post-treatment (b) result in mixed-type melasma. Rated score 4 by an independent observer



**Figure 3** Pretreatment (a) and post-treatment (b) result in mixed-type melasma. Rated score 4 by patient herself

different available modalities such as bleaching creams, chemical skin peeling, microdermabrasion, IPL, and QS Nd:YAG laser. The patients had not shown any appreciable improvement to treatments offered to them for at least six months; therefore, for the purpose of this study we treated them as one group of refractory melasma. Although epidermal melasma responds better to standard melasma therapy, the success rate could be quite variable. Some patients with melasma have hyperactive melanocytes, and topical agents may have limitations in inhibiting the melanogenesis in them. Moreover, a poor

correlation between classification of melasma based on Wood's light examination and skin biopsy samples assessed using light microscopy has been documented.<sup>15</sup> Therefore, in the light of recent advances in our understanding of the pathophysiology of melasma, the conventional model of depth distinction might not be the final word in indicating the treatment outcome in individual cases.

HQ alone or incorporated in TTT (modified Kligman's formula) is the most widely prescribed agent for treating melasma. Despite its efficacy, desquamation, burning,

**Table 3** Untoward effects of FPL (*n* = 65)

No.	Adverse effects of FPL	No. of cases according to Fitzpatrick skin type			Total
		III	IV	V	
1	Erythema > 24 h	x	2	3	5 (7.6%)
2	Burning > 24 h	x	x	x	x
3	Edema	x	x	x	x
4	Peeling	x	1	3	4 (6.1%)
5	Petechiae	x	x	x	x
6	Hypopigmentation	x	x	x	x
7	Hyperpigmentation	x	x	x	x

FPL, fluorescent pulsed light.

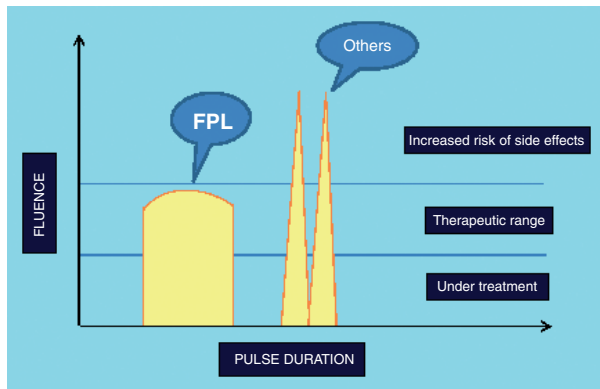
dryness, and pruritus are its frequently reported side effects.<sup>2</sup> Over the years, there has also been increasing concern on the occurrence of exogenous ochronosis due to topical use of HQ.<sup>7,16</sup> An evidence-based review of the role of retinoid monotherapy in the treatment of pigmentary disorders showed adverse effects such as local skin irritation, erythema, and peeling ranging from mild to severe in severity.<sup>17</sup> On the other hand, a randomized clinical trial comparing 4% HQ with 5% ascorbic acid in melasma concluded that although HQ showed better subjective response, there was no statistical difference in calorimetric measures, and ascorbic acid was almost devoid of side effects.<sup>18</sup> Ascorbic acid decreases melanogenesis by interacting with copper at the active site of tyrosinase and by reducing dopaquinone by blocking dihydrochindol-2-carboxyl acid oxidation.<sup>7</sup> Ascorbic acid, however, is highly unstable in aqueous solution, and it was experimentally demonstrated that its stable ester MAP had better percutaneous absorption into the epidermis, and 1.6% remained 48 hours after its application.<sup>19</sup> Because of the documented reliable inhibitory effect of MAP on melanogenesis, its antioxidant properties and better toxicity profile over HQ and other peeling agents, we designed the study to use 5% MAP cream as the topical bleaching agent along with FPL for treating our patients with refractory melasma.

Many different types of lasers and IPL devices have been used to treat melasma. The pigment-specific lasers such as QS Nd:YAG, QS ruby, and QS alexandrite have shown variable results.<sup>2</sup> Confetti-like hypopigmented macules were described in Asian patients treated with a low-fluence QS Nd:YAG (1064 nm) laser for skin rejuvenation and melasma.<sup>19,20</sup> Because of the promising results shown by 1550 nm fractional photothermolysis (FPT), it is currently the only laser modality approved by FDA (USA) for treating this disorder. However, the review of

published studies on the effectiveness of FPT in treating melasma showed that this might not be an ideal treatment choice for darker skin complexions. In a pilot study done to treat melasma with FPT in 10 patients, it was found that six patients had 75–100% clearing of melasma based on clinical evaluation. The four patients who did not respond were Hispanic with Fitzpatrick skin type V.<sup>21</sup> An open clinical study on treatment of melasma in 25 Asian patients using fractional 1550 nm laser recommended judicious use of FPT for treating Asian skin because of its limited efficacy.<sup>22</sup> Recently a split face study on 14 female patients with melasma treated with non-ablative FPT (1540 nm) showed good results in skin types I and II but emphasized its critical evaluation in patients with darker skin complexions.<sup>23</sup> A study analyzing histological and electron microscopic changes after fractional resurfacing suggested that the clinical improvement should not be interpreted as a cure for melasma.<sup>4</sup>

Several studies documented favorable outcomes in patients with melasma treated with IPL.<sup>24–26</sup> Improvement of refractory melasma was reported in 31 Taiwanese women (skin types III–IV) in whom the melanin index score decreased from  $66.1 \pm 24.7$  at baseline to  $39.8 \pm 22.6$  at week 16 after four IPL sessions. Similarly, 89 Chinese women treated with four IPL sessions three weeks apart showed a reduction in mean MASI score from 15.2 to 5.2. However, in some of these IPL-treated cases, darkening and sloughing of skin at treated sites, microcrust formation, postinflammatory hypopigmentation, and hyperpigmentation were reported. The overall view on the effectiveness of IPL is that it gives modest improvement in patients with melasma refractory to topical therapy alone and is perhaps appropriate for patients who do not mind 1–2 weeks recovery time.<sup>7</sup>

Owing to the higher melanin content in Asian skin, postinflammatory hyperpigmentation is the most frequent complication of lasers and light-based treatments. It has been proposed that pre- and postoperative use of topical bleaching agents make these procedures safer and more effective. Sun protection and avoidance can further reduce this risk.<sup>27</sup> To some extent, these interventions can correct the functional abnormality of melanocytes. This explains the better outcome documented in patients with melasma treated with CO<sub>2</sub> fractional ablative resurfacing along with topical application of HQ-based TTT cream, compared to those treated with either of these modalities alone.<sup>28</sup> The management protocol adapted in our study was based on these observations and recommendations. The topical application of 5% MAP cream was prescribed as a bleaching agent three weeks before starting FPL sessions. It was used as a daily application on affected areas at night and was continued three weeks after the last FPL session. Patients were instructed to



**Figure 4** The square-shaped pulse emitted by FPL device compared to pulse shape from other non-coherent light sources. FPL, fluorescent pulsed light

apply sun block cream with SPF-60 throughout the period of observation. These measures proved effective, and we did not encounter any case of postinflammatory hyperpigmentation. The advanced fluorescence technology device used in the study emits FPL, which is a non-coherent light (Fig. 4) that differs from light emitted by other IPL systems by its lower peak power, longer pulse width, and equally distributed fluence.<sup>29</sup> While designing the study, we anticipated that its lower peak power, which nevertheless was within the therapeutic range, would reduce the risk of untoward effects that could possibly be seen in pigmented skin. To further minimize such risks, we used lower energy densities ranging from 12 to 14 J/cm<sup>2</sup> and pulse widths of 15 ms. Similar parameters were used in an earlier study in which FPL was successfully used to treat pigmentary ochre dermatitis secondary to chronic venous insufficiency. The normal skin color was restored, no side effects were registered, and no repigmentation was observed at six months follow-up.<sup>11</sup>

In our patients with refractory melasma, FPL treatments combined with 5% MAP gave encouraging results, and the baseline mean MASI score of  $14.80 \pm 3.4$  decreased to  $4.53 \pm 1.5$  at the end of treatment in the 12th week. During the next 12 weeks of follow-up, patients were using only sunblock with SPF-60. The mean MASI score evaluated at the end of the follow-up period was increased to  $6.35 \pm 2.4$ . The overall regression in mean MASI scores at these two endpoints were 69.3% and 57%, which were statistically significant ( $P < 0.01$ ). We speculate that this beneficial response to treatment was due to the additive effect of the two treatment modalities used in our study. The 5% MAP contributed inhibitory effect on melanogenesis and free radical production,<sup>10</sup> while FPL (570–950 nm) worked on the principle of selective photothermolysis targeting the melanosomes, causing thermal denaturation and possibly

mechanical injury by rapid thermal expansion.<sup>30</sup> Future work at cellular level would be needed to elucidate exact mechanism.

The subjective assessments done by an independent observer and by patients themselves at the 12th week showed good to excellent response (scores 3 and 4) in 52.3% and 44.6% cases, respectively. Table 2 highlights the comparative scores of these two assessments, which do not differ significantly. However, the relatively lower satisfaction rate among the patients could be due to their higher expectations from the treatment. The suboptimal response in some patients (scores 1 and 2) could be because either they did not strictly follow the instruction to avoid sun or perhaps they had a higher proportion of active dermal melanophages not adequately targeted during the planned period of treatment. Possibly the desirable results in these patients could be achieved by prolonging the duration of treatment with an increased number of FPL sessions.

The treatment was well tolerated by all the patients in our study, and no significant adverse effects were registered either due to 5% MAP or FPL. Erythema persisting for more than 24 hours in five (7.6%) patients and mild skin peeling in four (6.1%) patients at FPL-treated sites subsided spontaneously without any additional treatment. These effects occurred in patients with Fitzpatrick skin types IV and V after FPL sessions done at the fluence of 14 J/cm<sup>2</sup>. This suggests that the lower fluence should be selected for light-based treatments in patients with a darker skin color. No burning, edema, petechiae, hypopigmentation, postinflammatory, or rebound hyperpigmentation was observed in any case.

In this study, we demonstrated that the combination of 5% MAP and FPL at settings used in our study is effective and safe in treating refractory melasma in Asian patients. There was appreciable patient satisfaction and no downtime. The suppression of melanogenesis was fairly sustained, and at the end of three months post-treatment follow-up, there was modest increase in mean MASI score indicating gradual recurrence of melasma. This implies that for persistent improvement, maintenance treatments would be required and a study with longer follow-up (possibly up to 12 months) is in order.

## References

- Sheth VM, Pandya AG. Melasma: a comprehensive update (part-I). *J Am Acad Dermatol* 2011; 65: 689–697.
- Gupta AK, Gover MD, Nouri K, et al. The treatment of melasma: a review of clinical trials. *J Am Acad Dermatol* 2006; 55: 1048–1065.
- Bandyopadhyay D. Topical treatment of melasma. *Indian J Dermatol* 2009; 54: 303–309.

- 4 Goldberg DJ, Berlin AL, Phelps R. Histologic and ultrastructural analysis of melasma after fractional resurfacing. *Lasers Surg Med* 2008; 40: 134–138.
- 5 Karoon MW, Wind BS, Beek JF, *et al.* Nonablative 1550-nm fractional laser therapy versus triple topical therapy for the treatment of melasma: a randomized controlled pilot study. *J Am Acad Dermatol* 2011; 64: 516–523.
- 6 Wind BS, Karoon MW, Meesterers AA, *et al.* Non-ablative 1,550 nm fractional laser therapy versus triple topical therapy for the treatment of melasma: a randomized controlled split-face study. *Lasers Surg Med* 2010; 42: 607–612.
- 7 Sheth VM, Pandya AG. Melasma: a comprehensive update (part-II). *J Am Acad Dermatol* 2011; 65: 699–714.
- 8 Park JM, Tsao H, Tsao S. Combined use of intense pulsed light and Q-switched ruby laser for complex dyspigmentation among Asian patients. *Lasers Surg Med* 2008; 40: 128–133.
- 9 Angsuwarangsee S, Polnikorn N. Combined ultrapulse CO<sub>2</sub> laser and Q-switched alexandrite laser compared with Q-switched alexandrite laser alone for refractory melasma: split-face design. *Dermatol Surg* 2003; 29: 59–64.
- 10 Kameyama K, Sakai C, Kondoh S, *et al.* Inhibitory effect of magnesium L-ascorbyl-2-phosphate (VC-PMG) on melanogenesis in vitro and in vivo. *J Am Acad Dermatol* 1996; 34: 29–33.
- 11 Pimentel CL, Rodriguez-Salido MJ. Pigmentation due to stasis dermatitis treated successfully with a noncoherent intense pulsed light source. *Dermatol Surg* 2008; 34: 950–951.
- 12 Ross EV. Laser versus intense pulsed light: competing technologies in dermatology. *Lasers Surg Med* 2006; 38: 261–272.
- 13 Taylor A, Pawaskar M, Taylor SL, *et al.* Prevalence of pigmentary disorders and their impact on quality of life: a perspective cohort study. *J Cosmet Dermatol* 2008; 7: 164–168.
- 14 Grimes PE. Management of hyperpigmentation in darker racial ethnic groups. *Semin Cutan Med Surg* 2009; 28: 77–85.
- 15 Kang HY, Ortonne JP. What should be considered in treatment of melasma? *Ann Dermatol* 2010; 22: 373–378.
- 16 Ribas J, Schettini APM, Cavalcante MSM. Exogenous ochronosis hydroquinone induced: a report of four cases. *An Bras Dermatol* 2010; 85: 699–703.
- 17 Kang HY, Valerio L, Bahadoran P, *et al.* The role of topical retinoids in the treatment of pigmentary disorders: an evidence-based review. *Am J Clin Dermatol* 2009; 10: 251–260.
- 18 Espinal-Perez LE, Moncada B, Castanedo-Cazares JP. A double-blind randomized trial of 5% ascorbic acid vs. 4% hydroquinone in melasma. *Int J Dermatol* 2004; 43: 604–607.
- 19 Wattanakrai P, Mornchan R, Eimpunth S. Low-fluence Q-switched neodymium-doped yttrium aluminum garnet (1,064 nm) laser for the treatment of facial melasma in Asians. *Dermatol Surg* 2010; 36: 76–87.
- 20 Chan NPY, Ho SGY, Shek SYN, *et al.* A case series of facial depigmentation associated with low fluence Q-switched 1,064 nm Nd:YAG laser for skin rejuvenation and melasma. *Lasers Surg Med* 2010; 42: 712–719.
- 21 Rokhsar CK, Fitzpatrick RE. The treatment of melasma with fractional photothermolysis: a pilot study. *Dermatol Surg* 2005; 31: 1645–1650.
- 22 Lee HS, Won CH, Lee DH, *et al.* Treatment of melasma in Asian skin using a fractional 1,550-nm laser: an open clinical study. *Dermatol Surg* 2009; 35: 1499–1504.
- 23 Barysch MJ, Rummelein B, Kolm I, *et al.* Split-face study of melasma patients treated with non-ablative fractionated photothermolysis (1540 nm). *J Eur Acad Dermatol Venereol* 2012; 26: 423–430.
- 24 Babilans P, Schreml S, Szeimies RM. Intense pulsed light (IPL): a review. *Lasers Surg Med* 2010; 42: 93–104.
- 25 Li YH, Chen JZ, Wei HC, *et al.* Efficacy and safety of intense pulsed light in treatment of melasma in Chinese patients. *Dermatol Surg* 2008; 34: 693–701.
- 26 Wang CC, Hui CY, Sue YM, *et al.* Intense pulsed light for the treatment of refractory melasma in Asian persons. *Dermatol Surg* 2004; 30: 1196–1200.
- 27 Chan HHL. Effective and safe use of lasers, light sources, and radiofrequency devices in the clinical management of Asian patients with selected dermatoses. *Lasers Surg Med* 2005; 37: 179–185.
- 28 Trelles MA, Velez M, Gold MH. The treatment of melasma with topical creams alone, CO<sub>2</sub> fractional ablative resurfacing alone, or a combination of the two: a comparative study. *J Drugs Dermatol* 2010; 9: 315–322.
- 29 Orenstien A, Lepselter J. Modular light-based system with Advanced Fluorescence Technology (AFT) for the treatment of cosmetic and aesthetic skin irregularities. 2004. [www document]. URL [http://www.almalasers.com/apps/download\\_files/229/AFT.pdf](http://www.almalasers.com/apps/download_files/229/AFT.pdf)
- 30 Dierickx CC. Laser treatment of pigmented lesions. In: Goldberg DJ, ed. *Laser Dermatology*. Berlin: Springer-Verlag, 2010: 37–60.